

## Giant cell tumors of bone localized in distal radius

Giant cell tumors in distal radius

Ismail Burak Atalay, Recep Öztürk, Mehmet Akif Şimşek, Yusuf İkbal Erdoğan, Bedii Şafak Güngör  
Department of Orthopaedics and Traumatology, Dr Abdurrahman Yurtaslan Ankara Oncology Training and Research Hospital, Ankara, Turkey

### Abstract

**Aim:** The aim of this study is to analyze the results of surgical treatment of patients with giant cell tumor in the distal radius according to the Campanacci grade. **Material and Method:** The data of 20 patients with giant cell tumor localized in the distal radius were analyzed retrospectively. 5 patients were Campanacci grade I, 13 patients were grade II and 2 patients were grade III. Patients with Grade I and II lesions underwent intralesional curettage + adjuvant treatments. Patients with Grade III underwent en bloc resection + reconstruction. **Results:** The mean age of 6 male and 14 female patients was 28.6 years. Recurrence developed in a total of 7 (35%) patients after the surgery in approximately 9 months. Post-operative complications developed in 2 patients (10%). There was no significant difference between the surgical approaches performed according to the tumor grade. **Discussion:** Intralesional curettage treatment is recommended for Campanacci grade I tumors and en bloc resection is recommended for grade II and III tumors.

### Keywords

Giant Cell Tumor; Distal Radius; Surgical Treatment

DOI: 10.4328/ACAM.20011 Received: 26.03.2019 Accepted: 10.04.2019 Published Online: 13.04.2019 Printed: 01.05.2020 Ann Clin Anal Med 2020;11(3):175-178

Corresponding Author: Recep Öztürk, Dr Abdurrahman Yurtaslan Ankara Oncology Training And Research Hospital, Demetevler Mah. Vatan Cad. 06200 Yenimahalle, Ankara, Turkey.

GSM: +905054634794 F.: +90 3123340352 E-Mail: ozturk\_recep@windowlive.com

ORCID ID: <https://orcid.org/0000-0002-6753-9321>

## Introduction

The giant cell tumor (GCT) of the bone is a benign but locally aggressive tumor. It constitutes 5% of all primary bone tumors [1]. Distal radius is the 3rd most common tumor site after distal femur and proximal tibia [2]. The lesion is often characterized by thinning and expansion in the cortex and may include a soft tissue component. It is frequently seen in adults between 20 and 40 years of age and is more common in women than in men [1,3].

GCT of bone is relatively uncommon and it is a weird tumor because of its unpredictable nature. While some cases are extremely benign, some may be aggressive and lung metastasis can be seen [4]. The proximity to the joint and to especially median nerve makes the resection of tumor and reconstruction of the tumor site hard in the tumors localized in distal radius [2,4]. Surgical treatment of GCTs of bone includes isolated curettage, curettage, and adjuvant therapy (e.g, high-speed burring, phenol, cryotherapy), en bloc resection and defect reconstruction or arthrodesis methods [4]. Although it is not known which of these methods is the most appropriate treatment method, the biggest problem after the treatment is high recurrence rates which can be high as 65%. Recurrence rates have been reported between 27-65% after isolated curettage, 27% after curettage and adjuvant treatment and can reach 12% after en bloc resection [1,5]. Besides these findings, en bloc resection procedure is an approach that sacrifices the surface of the joint and secondary arthritis is seen in close to 50% of the patients [4,6].

## Material and Methods

This study retrospectively collected clinical data of patients with distal radius localized GCT between January 2008 and December 2018. Inclusion criteria were the patients diagnosed with GCT by a biopsy performed on the distal radius in Ankara Oncology Training and Research Hospital. The precise location of the tumor was confirmed by X-ray and MRI in our hospital. The exclusion criteria were as follows; patients with a previous history of surgery and patients undergoing non-surgical treatment.

All the participants who are legally responsible or first-degree relatives of the patient in the study gave their informed consent prior to the commencement of the research. Written informed consent was obtained from the patient's legal custodian or first-degree relatives for publishing the individual medical records. Surgical points: Individual surgical treatment choices were selected according to the Campanacci grade of the tumor (Table 1) [8]. In curettage patients, adjuvant burr was applied to the lesion site with both cauterization and burring for grind lesions after curettage. Then 95% ethanol was used to neutralize the tumor site. The extent of osteotomy was determined according to preoperative imaging findings in patients who underwent en bloc resection. Autologous fibular graft, allogeneic bone graft segment, iliac graft or combinations were used for the reconstruction of the radiocarpal joint after en bloc resection (table I).

Functional evaluation: The Musculoskeletal Tumor Society Score (MTSS) was used to assess limb function [7]. The system consisted of six items including pain, overall function, psychological level, gesture, sensitivity, and muscle strength. The functional result was assessed as excellent (30-24 scores), good (23-18 scores), fair (17-12 scores) or poor (<12 scores) using the grading scheme.

## Statistical analysis

The mean follow-up period of 20 patients was 48.5 months (range 12 to 125 months). All statistical analyses were performed using IBM SPSS 22.0 statistical software (IBM Corp., Armonk, NY, USA). Descriptive statistics are expressed as mean  $\pm$  standard deviation, frequency, and percentage.  $P < 0.05$  was considered to indicate a statistically significant difference.

## Results

Preoperative patients' characteristics: 20 patients with distal radius localized GCT were included in the study from January 2008 to December 2018. Six (6) of them were male and 14 of them were female. The mean age was 28.6 years (range, 15-44 years). All lesions were graded radiologically according to the grading system of Campanacci et al. [8]. There were 5 cases in grade I, 13 cases in grade II and 2 cases in grade III according to the Campanacci's grading system. The clinical data of the patients are shown in Table 1.

Postoperative recurrence: The recurrence of tumor occurred in a total of 7 patients (35.0%) after 9 months of surgery (between 8 and 15 months). Curettage and cementation were applied to the patients who was grade 2 according to the Campanacci's grading system. En bloc resection, autograft fibula and allograft radius for the joint reconstruction was applied for the treatment of recurrence of this patient. Curettage grafting was applied for the patient's recurrence who had grade 2 and had been applied curettage grafting. Soft tissue resection was applied for the recurrence of 4 patients (one of them was grade 3 and had been applied en bloc resection + reconstruction with fresh frozen radius, 3 of them were grade 2 and had been applied curettage and grafting) due to the recurrence was in the soft tissue. En bloc resection and wrist arthrodesis with allograft fibula were applied to a patient who had grade 2 and had undergone curettage and cementation.

Postoperative complications: Arthrodesis with autogenous fibula was applied to a patient who was grade 2 and had undergone curettage grafting due to fracture complication. Pseudoarthritic tissues were removed, and an autogenous fibula + autogenous

**Table 1.** Basic features of 20 patients with distal radius localized giant cell tumor

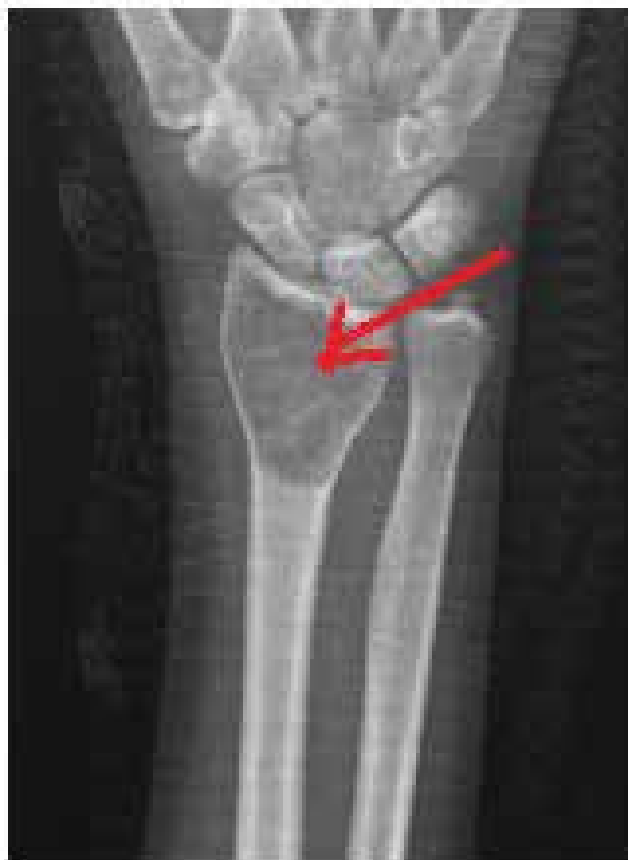Characteristic	No. patients
Mean age, years (range)	28,6 (15-44 year old)
Gender (male/female)	6/14
Campanacci's Grade	
Grade I	5
Grade II	13
Grade III	2
Surgical regimens	
Group A	18
Group B	2
Follow-up time, months (range)	48,5(12-125 months)

Group A, curettage, inactivated tumor bed and allogeneic bone graft/bone cement augmentation; Group B, en bloc resection and reconstruction with fibular autograft/allogeneic bone graft

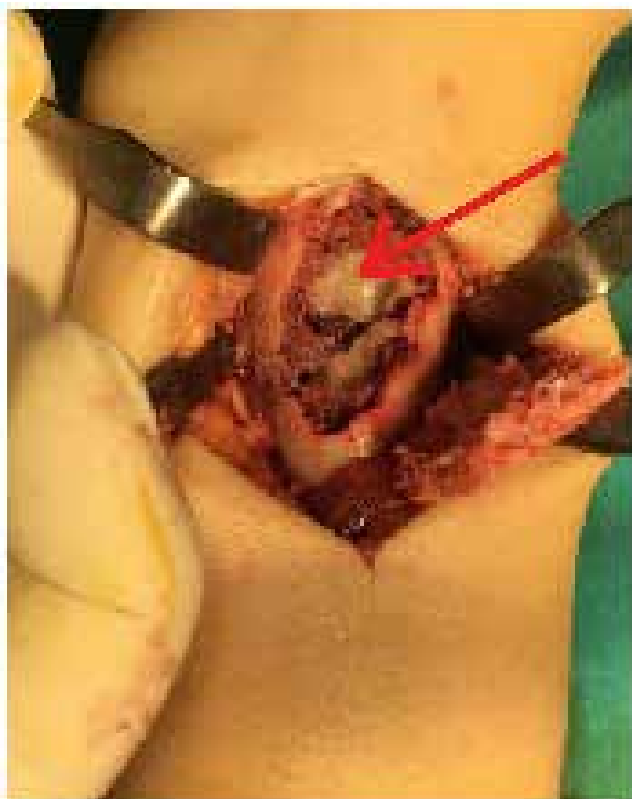**Table 2.** Postoperative recurrence and complications in the two groups.

Outcome	Group A (n=18)	Group B (n=2)
Recurrence	6	1
Infection	0	0
Internal fixation fracture	1	0
Nonunion	0	1
Total	7	2

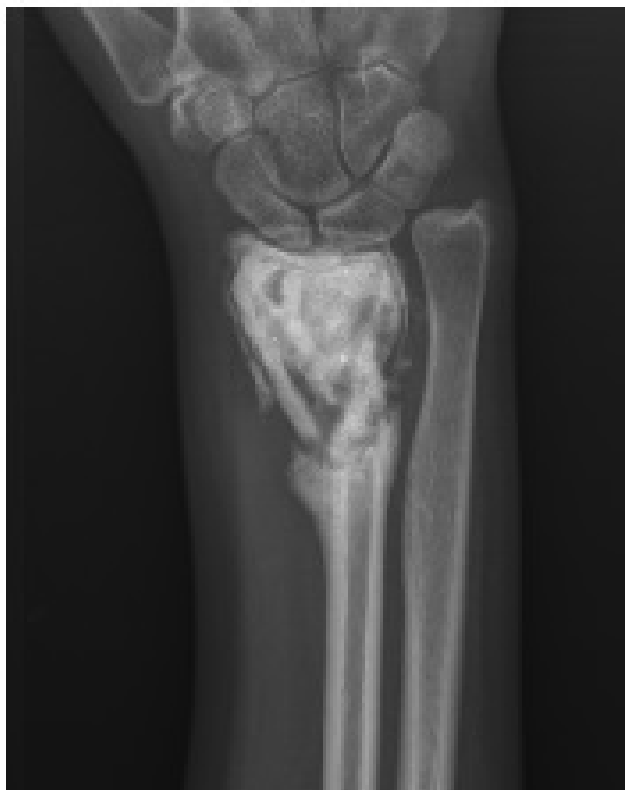iliac graft and radiocarpal arthrodesis were performed to a patient who was Grade 3 and had undergone en bloc resection and allograft fibula + iliac autograft due to nonunion complication (Table 2).



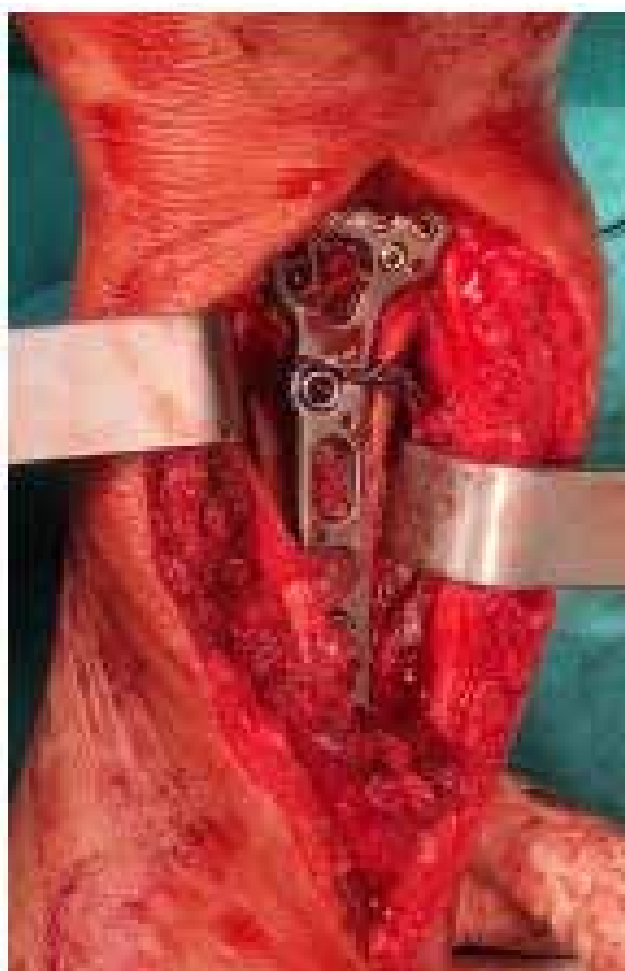
**Figure 1.** Radiograph of one of the patients with a distal localized giant cell tumor (red arrow showing the tumoral lesion)



**Figure 2.** Intraoperative image of a distal radius localized giant cell tumor (red arrow showing tumoral lesion)



**Figure 3.** Post-operative 8-months recurrence image after curettage + cementation



**Figure 4.** Allograft fibula and iliac autogenous graft after en bloc resection was stabilized with distal radius plate

The incidence of postoperative recurrence was 33% (6/18) in Group A and 50% (1/2) in Group B, and the statistical P value was >0.05.

Post-operative complications developed in 2/20 (10%) of the patients (table 2). There were no statistically significant differences in the incidence of complications between two surgical approaches of GCT ( $P > 0.05$ ).

Functional outcomes: The mean follow-up period of 20 patients was 48.5 months (range 12 to 125 months). Functional MTSS results were excellent in 6 cases (30%), good in 8 cases (40%), moderate in 4 cases (20%), and poor in 2 cases (10%). Generally, the excellent and good rate was 70%.

## Discussion

Distal radius localized GCTs occur in young population between 20 and 40 years of age. This group is difficult to manage in terms of normal functional life expectancy of the patient [2, 9]. Local recurrence and loss of range of motion are difficulties for the surgeons about which surgery should be performed. Although there is no consensus on the most appropriate surgical method, curettage and bone grafting generally protect the wrist function, but a high recurrence rate is observed [10,11]. The en bloc resection provides local control close to 100%, but the cost is the loss of limb function [12].

Liu et al. in their meta-analysis studies, found that the recurrence rate after intralesional curettage treatment in Campanacci grade 3 cases was higher than the en bloc resection [4]. There were two cases in the grade 3 and we performed en bloc resection on both and no recurrence was observed in the follow-up in our series.

We applied curettage and cauterization + burr as an adjuvant in cases of Campanacci grade 1. We also augmented the defect with graft or cement and did not experience any recurrence in 5 patients.

The most challenging group in our study were grade 2 cases. Curettage treatment was applied to all 13 cases, grafting to 11, cementation to 2 and the recurrence rate was 46%. According to the literature, the reason for this high recurrence rate is the limited number of cases. In addition, the recurrence of one of the 2 patients who were cemented may give an idea of the fact that the cementation is not superior to grafting in terms of recurrence.

The complication rates vary according to the surgical treatment of the GCTs of the distal radius. Previous studies have found that the rates of complications after en bloc resection were higher than those after curettage [1,13,14]. In our study, the result was similar, and one of the 2 patients who underwent resection developed complications.

In the literature, many complications such as nonunion, fracture, subluxation, postoperative pneumonia, arthritis, and infection have been reported after distal radius GCT surgery [1,13,14]. A case of nonunion was seen in the allograft-radius junction in our study. We think that the cause may be a slow progressive creeping substitution in allografts. In our case, the reason for preferring radiocarpal arthrodesis was the presence of diffuse defect area and the destruction of the articular surface.

Patients with distal radius GCT may experience long-term survival unless there is an incidence of pulmonary metastasis or a change to malignancy; therefore, the functional recovery of the wrist is extremely important. In this study, allograft radius or autogenous iliac crest was used in patients who underwent en bloc resection for the protection of the joint function as much as possible.

In this study, we suggest that en bloc resection and reconstruction can be used as the first-choice standard treatment method for the Campanacci grade 2 distal radius localized GCTs.

This study had some limitations. It was primarily a retrospective analysis and treatment was planned for each patient according to the approach of the current surgeon during treatment. Secondly, the same surgeon did not make the surgery of all cases. In addition, the number of cases was relatively low due to the fact that it was a rare tumor. We could not get enough statistical results due to more than one treatment alternatives. Further studies with a high number of patients are needed in the future.

## Conclusion

Intralesional curettage treatment is recommended for Campanacci grade I tumors and en bloc resection is recommended for grade II and III tumors.

### Scientific Responsibility Statement

The authors declare that they are responsible for the article's scientific content including study design, data collection, analysis and interpretation, writing, some of the main line, or all of the preparation and scientific review of the contents and approval of the final version of the article.

### Animal and human rights statement

All procedures performed in this study were in accordance with the ethical standards of the institutional and/or national research committee and with the 1964 Helsinki declaration and its later amendments or comparable ethical standards. No animal or human studies were carried out by the authors for this article.

### Funding: None

### Conflict of interest

None of the authors received any type of financial support that could be considered potential conflict of interest regarding the manuscript or its submission.

## References

- Zhang J, Li Y, Li D, Xia J, Li S, Yu S, et al. Clinical effects of three surgical approaches for a giant cell tumor of the distal radius and ulna. *Mol Clin Oncol*. 2016; 5(5): 613-7. Doi: 10.3892/mco.2016.1031.
- Salunke AA, Shah J, Warikoo V, Chakraborty A, Pokharkar H, Chen Y, et al. Giant cell tumor of distal radius treated with ulnar translocation and wrist arthrodesis. *J Orthop Surg (Hong Kong)*. 2017; 25(1): 1-6. Doi: 10.1177/2309499016684972.
- Niu X, Zhang Q, Hao L, Ding Y, Li Y, Xu H, et al. Giant cell tumor of the extremity: retrospective analysis of 621 Chinese patients from one institution. *J Bone Joint Surg Am*. 2012; 94: 461-7. doi: 10.2106/JBJS.J.01922.
- Liu YP, Li KH, Sun BH. Which treatment is the best for giant cell tumors of the distal radius? A meta-analysis. *Clin Orthop Relat Res*. 2012; 470(10): 2886-94. doi: 10.1007/s11999-012-2464-7.
- Chakarun CJ, Forrester DM, Gottsegen CJ, Patel DB, White EA, Matcuk GR Jr. Giant cell tumor of bone: Review, mimics, and new developments in treatment. *Radiographics*. 2013; 33: 197-211. doi: 10.1148/rg.331125089.
- Harness NG, Mankin HJ. Giant-cell tumor of the distal forearm. *J Hand Surg Am*. 2004; 29: 188-93. Doi: 10.1016/j.jhssa.2003.11.003.
- Enneking WF, Dunham W, Gebhardt MC, Malawar M, Pritchard DJ. A system for the functional evaluation of reconstructive procedures after surgical treatment of tumors of the musculoskeletal system. *Clin Orthop Relat Res*. 1993; 241-6.
- Campanacci M (ed): *Bone and Soft Tissue Tumors: Clinical Features, Imaging, Pathology, and Treatment*. Springer-Verlag, Vienna, Austria, 1999.
- Öztürk R, Arıkan ŞM, Bulut EK, Kekeç AF, Çelebi F, Güngör BŞ. Distribution and evaluation of bone and soft tissue tumors operated in a tertiary care center. *Acta Orthop Traumatol Turc*. doi: 10.1016/j.aott.2019.03.008.
- Eckardt JJ, Grogan TJ. Giant cell tumour of bone. *Clin Orthop*. 1986; 204: 45-58.
- Klenke FM, Wenger DE, Inwards CY, Rose PS, Sim FH. Giant cell tumor of bone: risk factors for recurrence. *Clin Orthop Relat Res*. 2011; 469: 591-9. doi: 10.1007/s11999-010-1501-7.
- Su YP, Chen WM, Chen TH. Giant-cell tumors of bone: An analysis of 87 cases. *Int Orthop*. 2004; 28: 239-43. Doi: 10.1007/s00264-004-0564-z
- Cheng CY, Shih HN, Hsu KY, Hsu RW. Treatment of giant cell tumor of the distal radius. *Clin Orthop Relat Res*. 2001; 383: 221-8.
- Panchwagh Y, Puri A, Agarwal M, Anchan C, Shah M. Giant cell tumor-distal end radius: Do we know the answer? *Indian J Orthop*. 2007; 41: 139-45. doi: 10.4103/0019-5413.32046.

### How to cite this article:

Atalay IB, Öztürk R, Şimşek MA, Erdoğan YI, Güngör BŞ. Giant cell tumors of bone localized in distal radius. *Ann Clin Anal Med* 2020;11(3):175-178