

## The learning curve in minimally invasive cardiac surgery procedures: a single surgeon experience

Less invasive cardiac surgery

Kenan Abdurrahman Kara  
Department of Cardiovascular Surgery, Yeditepe University Hospital, Ataşehir, Istanbul, Turkey

### Abstract

**Aim:** With the development of technology and surgical techniques, minimally invasive surgical approaches are being preferred by surgeons in cardiac surgery. Smaller incisions with these approaches provide a faster recovery and higher life quality in the early post-operative period. In this study, we report our experience with minimally invasive approaches in cardiac surgery. Primary end-point of the study was technical success and secondary was early discharge from the hospital. **Material and Method:** Eighteen patients that underwent open-heart surgery with minimally invasive approaches between 2016 and 2017 at Hisar Intercontinental Hospital were enrolled in the study. The median age was 53 (18–84) years, four were female (22%). J- mini-sternotomy was performed in four patients requiring aortic valve replacement, and in six patients CABG X1 with beating-heart. T-sternotomy in two CABG X2 procedures), in four patients requiring mitral valve replacement (MVR) and in two patients requiring ASD repair with right anterolateral mini-thoracotomy incision (4 MVR, 2 ASD). **Results:** The mean cross-clamp time was 57.75 min (approximately two times longer than conventional methods). All patients were extubated in ICU 4–6 h after the surgery. Early mortality (within 30 days after the surgery) was observed in only one patient due to non-cardiac reasons. No complications were observed from the surgical wound. **Discussion:** Minimally invasive surgery is gaining popularity, and patients prefer these procedures more often. Exposure of surgical field, performing better cases from small incisions are associated with the surgeon's learning curve. With the increasing experience, minimally invasive cardiac surgery can be considered for selected patients and especially for patients with high risk of wound complications who are obese, have diabetes, osteoporosis or small skin incision preferred for patients with aesthetic anxiety.

### Keywords

Minimally Invasive Cardiac Surgery; Small Skin Incision; Anterior Upper Minithoracotomy; Ministernotomy

DOI: 10.4328/JCAM.6043 Received: 06.10.2018 Accepted: 20.10.2018 Published Online: 23.10.2018 Printed: 01.03.2019 J Clin Anal Med 2019;10(2): 142-4  
Corresponding Author: Kenan Abdurrahman Kara, Yeditepe University Hospital Cardiovascular Surgery Department, Ataşehir, Istanbul, Turkey.  
GSM: +905300655225 F.: +90 2164693796 E-Mail: kenankaradoc@gmail.com  
ORCID ID: 0000-0003-1295-7689

## Introduction

Most of the cardiac surgery procedures are still involve incising via median sternotomy. This conventional approach provides surgeons to have better exposure and, therefore, confers more confidence during surgery. However, this approach can possibly induce fear in some patients owing to their chest being “cracked open” and also for some patients with high risk of wound complications with obesity, diabetes, and osteoporosis [1]. In many publications, it is said that patients who underwent less invasive surgery have less pain post operatively and return to the daily life in a short time. [2,5,6].

Minimally invasive cardiac surgery, when the heart can be accessed typically through the left or right mini-thoracotomy or mini-sternotomy, may alleviate this problem. The incision made is smaller as compared with that in the conventional approach, and the risks of wound infection following sternal trauma and sternum healing problems are avoided [1].

## Material and Method

Eighteen patients underwent cardiac surgery by minimally invasive approaches in Hisar Intercontinental hospital between 2016 and 2017. The mean age of the patients was 53 (18–84) years, and four of them were females [22%]. J-mini-sternotomy was performed in four patients requiring aortic valve replacement (AVR) and in six patients CABG X1 with beating-heart (Figure-1). T-sternotomy was performed in two CABG X2 (LAD-RCA and LAD-D1) procedures, in four patients requiring mitral valve replacement (MVR) and in two patients requiring ASD repair with right anterolateral mini-thoracotomy incision (Figure 2, Figure 3).

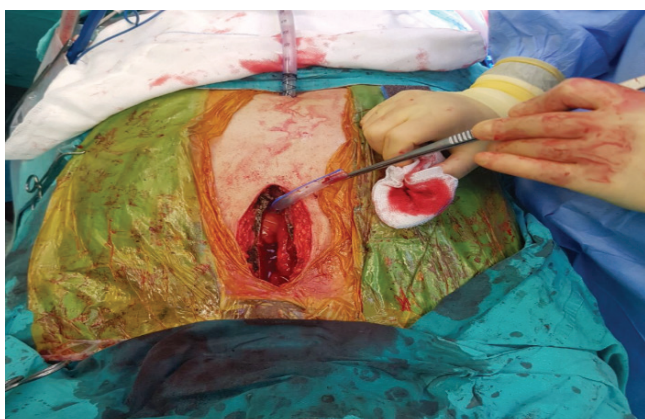

Figure 1. Post operative Aortic valve surgery

## Surgical Techniques

In the upper J-ministernotomy group for AVR, approximately 6–8 cm-long midline skin incision was made starting from the suprasternal notch. The sternum was divided down to the fourth intercostal space and angled right using an oscillating saw (J-shape). An inferior J- or T-shaped mini-sternotomy with 6–8cm skin incision was made in the CABG group. LIMA was harvested for all CABG patients. Cannulation was performed with conventional technique as ascending aorta and right atrial appendix for AVR and CABG patients. Additionally, for six patients, beating-heart CABG was performed with J-mini-sternotomy incisions.

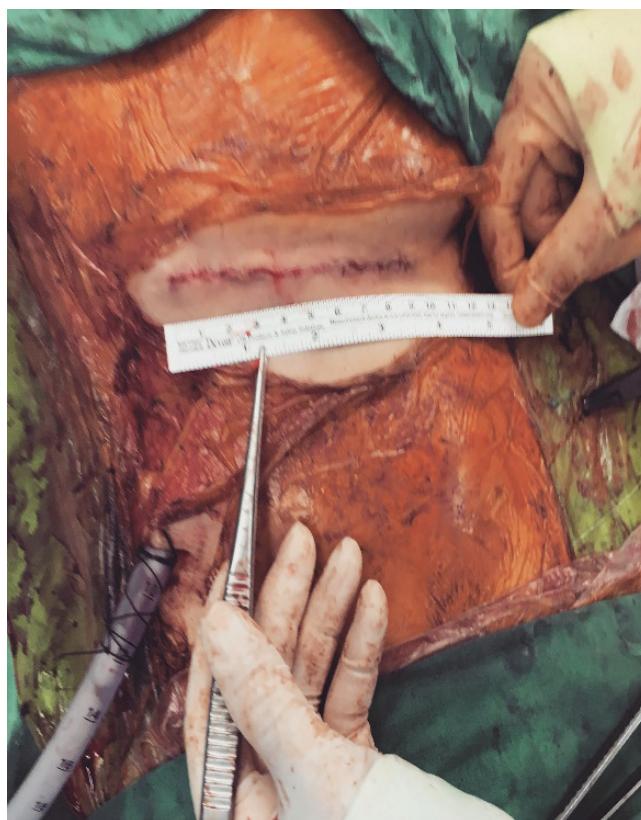

Figure 2. Post operative Mitral Valve Surgery

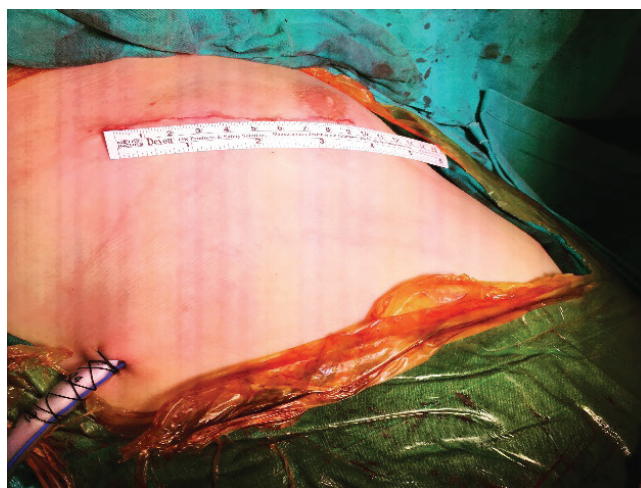


Figure 3. Post operative Mitral valve surgery

In the right anterolateral mini-thoracotomy patients, MVR and ASD closure procedures were performed with 7–10 cm skin incisions from 4–5 intercostal space. Conventional aorta, the bi-atrial selective technique was used for cannulation in all patients except one undergoing MVR, where right femoral vein cannulation was performed for inferior venous cannulation because of poor exposure. All operations were performed using the same anesthesia protocol, moderate hypothermic CPB (30°C–32°C), and isothermal blood cardioplegia. A 32Fr or 28Fr drainage tube was placed in the mediastinal or thoracic cavity before closure.

## Statistics Analysis

No statistical tests were used. Data were expressed as a mean  $\pm$  standard deviation.

## Results

Technically there were no complications for any patients. Only one patient cannulated from the right femoral vein for inferior venous cannulation due to a poor vision of vena cava inferior from anterolateral mini-thoracotomy incision. All patients were extubated in the ICU, 4–6 hours after surgery, and started mobilization in the evening of the operation, 8–10 hours after surgery. No cases of any arrhythmias or wound complications or re-hospitalizing for wound care were noted (Table 1).

Early mortality (within 30 postoperative days) was observed in one patient after one week discharged from hospital presented with multiple mycotic cerebral aneurysm ruptures with cranial hematoma and ended up in coma. MRI revealed that she had previous multiple saccular mycotic aneurysms.

Table 1. Operative data

CCT	57.75 min
ICU	1,2 day
Hospital day	4,6
Drainage	480ml
Extubation time	5,5 hour
Mobilization	9 hour
Age	53

CCT: Cross-clamp time; ICU: Intensive Care Unit

## Discussion

Minimally invasive surgery is gaining popularity and patients increasingly prefer these procedures. With adequate training and experience, the surgeon could perform these procedures. Exposure to the surgical field and the ability to make small incisions are dependent on the surgeon's learning curve. With increasing experience, minimally invasive cardiac surgery may be used as an alternative to conventional cardiac surgery in selected patients, especially in those who are particular about their appearances and skin wounds.

Less traumatic and smaller wounds provide patients more comfortable postoperative periods. Pain levels and daily life activities are the most important indicators of physical and psychological well-being [2]. In minimally invasive procedures, the incisions are smaller and the risk of wound infection is less [3]. Other possible benefits of this approach include a reduction in postoperative atrial fibrillation and reduced length of hospital stay with early patient mobilization [4–6].

However, there are some limitations to minimally invasive cardiac surgery. The difficulty of exposure with a right anterolateral mini-thoracotomy or J- or T- mini-sternotomy may account for an increase in operation time, cross-clamp time, and perioperative complications [7]. In the early hours of the post-operative period after mini-thoracotomy, patients may experience more pain due to the micro-injury of the intercostal nerves and excessive rib retraction during the procedure [4,8]. In opposite, in our study, starting from post-operative day-1, patients feel more comfortable and stay more mobile comparing with the conventional cardiac surgery post-operative patients. Additionally, the procedure is also more technically demanding [9].

## Conclusion

Minimally invasive procedures performed through right mini-thoracotomy or mini-sternotomy are safe and are associated with excellent postoperative outcomes in terms of mortality, morbidity, shorter intensive care unit and hospital stay, and faster recovery. It also provides less wound complications. On the contrary, cross-clamp and CPB times are longer than conventional surgeries; however, with an increase in surgical experience, the use of minimally invasive procedures will be preferred by more surgeons.

## Scientific Responsibility Statement

*The authors declare that they are responsible for the article's scientific content including study design, data collection, analysis and interpretation, writing, some of the main line, or all of the preparation and scientific review of the contents and approval of the final version of the article.*

## Animal and human rights statement

*All procedures performed in this study were in accordance with the ethical standards of the institutional and/or national research committee and with the 1964 Helsinki declaration and its later amendments or comparable ethical standards. No animal or human studies were carried out by the authors for this article.*

## Funding: None

## Conflict of interest

*None of the authors received any type of financial support that could be considered potential conflict of interest regarding the manuscript or its submission.*

## References

- Head S. J, Börgermann J, Osnabrügge R. L. J, Kieser T. M, Falk V, Taggart D. P, et al. Coronary artery bypass grafting: part 2-optimizing outcomes and future prospects. *Eur Heart J*. 2013; 34:2873–86.
- Özer T, Yücel M, Mataracı İ, Hanedan M. O, Sayar U, Emir İ. Minimally invasive cardiac surgery experiences in a district branch hospital. *Koşuyolu Heart Journal*. 2014; 17(2): 110–13. DOI: 10.4274/khj.85570
- Stamou S. C, Bafi A. S, Boyce S. W, Pfister A. J, Dullum M. K. C, Hill P. C, et al. Coronary revascularization of the circumflex system: different approaches and long-term outcomes. *Ann Thorac Surg*. 2000; 70: 1371–7.
- King R. C, Reece T. B, Hurst J. L, Shockey K. S, Tribble C. G, Spotniz W. D, et al. Minimally invasive coronary artery bypass grafting decreases hospital stay and cost. *Ann Surg*. 1997; 225: 805–9.
- Dogan S, Graubitz K, Aybek T, Khan M.F, Kessler P, Moritz A, et al. How safe is the port access technique in minimally invasive coronary artery bypass grafting? *Ann Thorac Surg*. 2002; 74: 1537–43.
- Detter C, Reichenspurner H, Boehm D.H, Thalhammer M, Schütz A, Reichart B. *Eur J Cardiothorac Surg*. 2001;19: 464–70.
- Dogan S, Dzemali O, Wimmer-Greinecker G, Derra P, Doss M, Khan M.F, et al. Minimally invasive versus conventional aortic valve replacement: a prospective randomized trial. *J Heart Valve Dis*. 2003;12:76–80.
- Güler M, Kirali K, Toker M.E, Bozbuğa N, Ömeroğlu A. E, Yakut C. Different CABG methods in patients with chronic obstructive pulmonary disease. *Ann Thorac Surg*. 2001; 71: 152–7.

## How to cite this article:

*Kara KA. The learning curve in minimally invasive cardiac surgery procedures: a single surgeon experience. J Clin Anal Med 2019;10(2): 142-4.*