

A case of candida spondylodiscitis in an immunocompetent patient

Candida osteomyelitis

Halil Er¹, Nisel Özkalay Yılmaz¹, Evren Sandal², Mehmet Şenoğlu²

¹Medical Microbiology Laboratory, University of Health Sciences, Tepecik Training and Research Hospital, Izmir

²Brain and Nerve Surgery Clinic, University of Health Sciences, Tepecik Training and Research Hospital, Izmir/TURKEY

This article is presented as an oral presentation at the "International XXXVIII Turkish Microbiology Congress" on 4-8 November 2018, Antalya.

Abstract

Spondylodiscitis caused by *Candida parapsilosis* is a rare clinical condition when there are underlying facilitating factors such as immunosuppression. In this case, we presented a *C. parapsilosis* spondylodiscitis in a patient without any immunosuppression.

A 54-year-old woman presented with low back pain lasting for two months. On the patient's resume, she had a history of hypertension and no history of another chronic disease. Furthermore, no immunosuppression was detected in the patient. Magnetic resonance and computerized tomography scans showed a lytic lesion in the posterior half of the T12 and L1 vertebral corpus. Dark blooded content was aspirated from and the lesion with the aspiration biopsy and *C. parapsilosis* growth was observed. According to the antibiotic susceptibility tests, fluconazole treatment was started and the lesion was regressed at the control MR after 5 months.

Candida spondylodiscitis is a rare clinical condition in immunocompetent patients. *Candida* spondylodiscitis should always be kept in mind among patients presenting with long-term low back pain.

Keywords

Candida spondylodiscitis

DOI: 10.4328/ACAM.20103 Received: 2020-01-02 Accepted: 2020-02-06 Published Online: 2020-02-17 Printed: 2020-04-01 Ann Clin Anal Med 2020;11(Suppl 1): S85-88

Corresponding Author: Halil Er, Medical Microbiology Laboratory, University of Health Sciences, Tepecik Training and Research Hospital, Izmir

E-mail: haliler004@hotmail.com GSM: +90 505 515 20 50

Corresponding Author ORCID ID: <https://orcid.org/0000-0002-8752-2156>

Introduction

Invasive candidiasis refers to bloodstream infections with *Candida* spp. and deep-seated infection such as intra-abdominal abscess, peritonitis (inflammation of the peritoneum, the tissue that covers the inner wall of the abdomen and abdominal organs) or osteomyelitis (infection of the bones) with or without candidaemia [1]. Risk factors for invasive candidiasis include recent surgery, intravenous drug use, the use of broad-spectrum antibiotics, chemotherapy, insertion of central venous catheters, and immunosuppression [1]. Vertebral *Candida* Osteomyelitis (VCO) was previously considered a complication of intravenous drug use, but now is mostly a health-care-associated infection, such as most invasive *Candida* infections [2]. Especially, very few data exist concerning VCO which account for approximately 1% of infectious spondylodiscitis [2]. In this study, we aimed to present a case of spondylodiscitis in immunocompetent a patient.

Case Report

A 54-year-old female patient who had low back pain for two months was admitted to the neurosurgery clinic of our hospital. Low back pain and stiffness are emerging with prolonged standing and rest. On the patient's resume, she had a history of hypertension and no history of another chronic disease. On examination, the patient described thoracolumbar pain with palpation and percussion. Laboratory findings showed microcytic anemia (11.3 g/dl) with sedimentation (84 mm/h) and CRP (42,5 mg/dl) elevation. Typhoid, paratyphoid, brucellosis, tuberculosis and viral serology (AntiHIV, HbsAg, Anti HCV etc.) were found to be negative.

Magnetic resonance (MRI) imaging scan revealed a lytic/cystic lesion in the posterior half of the T12 and L1 vertebrae corpus (Figure 1A). Lesions in both corpus have a connection in the disc space, there was no prominent pathology and contrast enhancement in disc areas other than this connection. Other vertebral segments were found normal.

Lumbar vertebrae computerized tomography (CT) scans showed a lytic lesion in the posterior half of the T12 and L1 vertebral corpus (Figure 1B). It was observed that the lesion boundaries reached the posterior surface of the vertebral corpus. Vertebrae rear elements were evaluated as usual.

Atypical vertebral infection or tumoral pathology was thought as prediagnosis because of the unaffected entire disk space, an absence of abscess-like pathology extending into the paravertebral and spinal canals, no significant elevation in infection parameters. Due to this preliminary diagnosis, it was decided to perform sampling before aggressive surgery.

The intense dark blooded content was aspirated by entering into the lytic lesion with a needle under local anesthesia and with CT guidance (Figure 1C). Concurrent blood cultures with aspiration samples were sent to the Medical Microbiology laboratory.

Samples sent to the microbiology laboratory were inoculated to suitable media and at the end of the incubation period, growth was detected on aspiration material and blood culture. Reproduced colonies were gram-stained and yeast cells were observed. Germ tube test, tween 80 agar inoculation, chromagar inoculation and identification with the API ID 32C

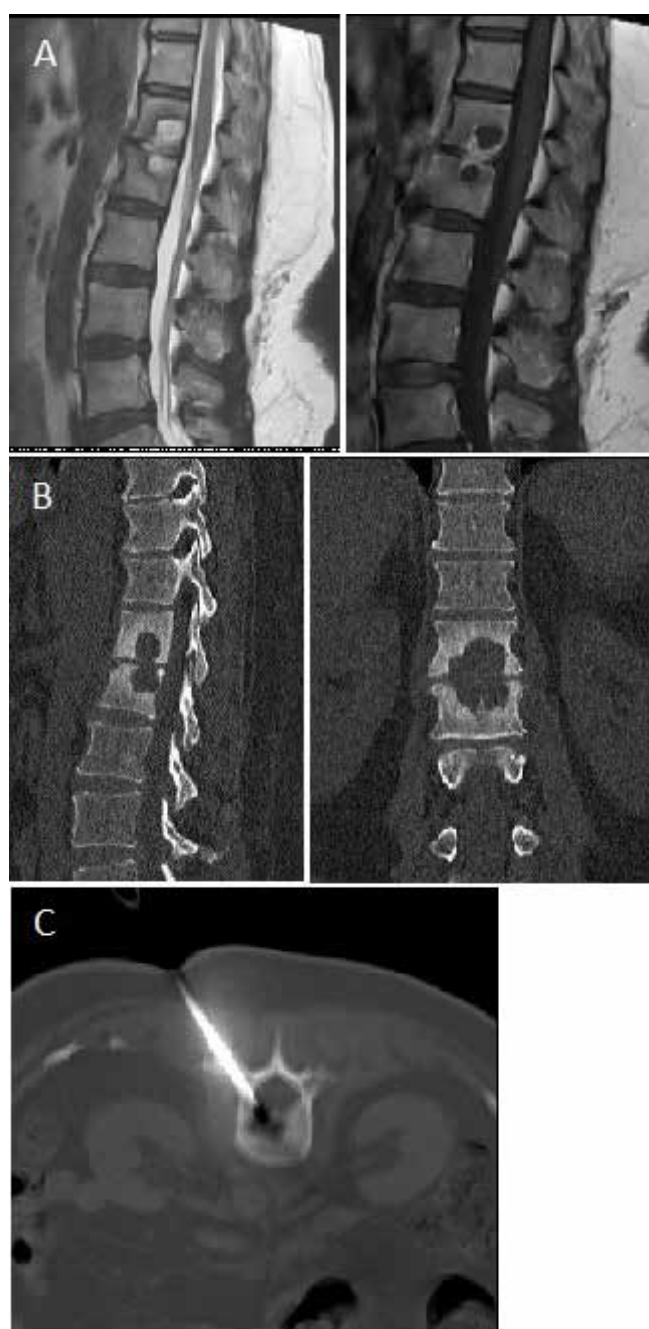


Figure 1. (A) MR imaging (B) CT imaging (C) CT-guided lesion aspiration

(BioMerieux, France) were made to the colonies and *Candida parapsilosis* growth was determined as a result.

Antifungal susceptibility test for fluconazole (FL), voriconazole (VOR), posaconazole (POS), itraconazole (ITR), anidulafungin (AND) and amphotericin B (AMP B) were applied to the isolated microorganism with gradient testing (MIC Test Strip, Liofilchem, Italy). Minimum inhibitory concentration (MIC) values were determined as 1 µg/ml, 0.023 µg/ml, 0.023 µg/ml, 0.064 µg/ml, 3 µg/ml and 0.25 µg/ml respectively. According to EUCAST criteria, FL, VOR, ITR, POS and AMP B were reported as sensitive, AND were reported intermediate.

Some progression of the lesion was detected by the recurrent vertebral MRI before the treatment (Figure 2). Also, the lesion was monitored at the entire disk range and anterior paravertebral area. Therefore, the patient was not planned for surgery and according to the antifungal susceptibility results, 6 mg/kg intravenous fluconazole treatment was started per

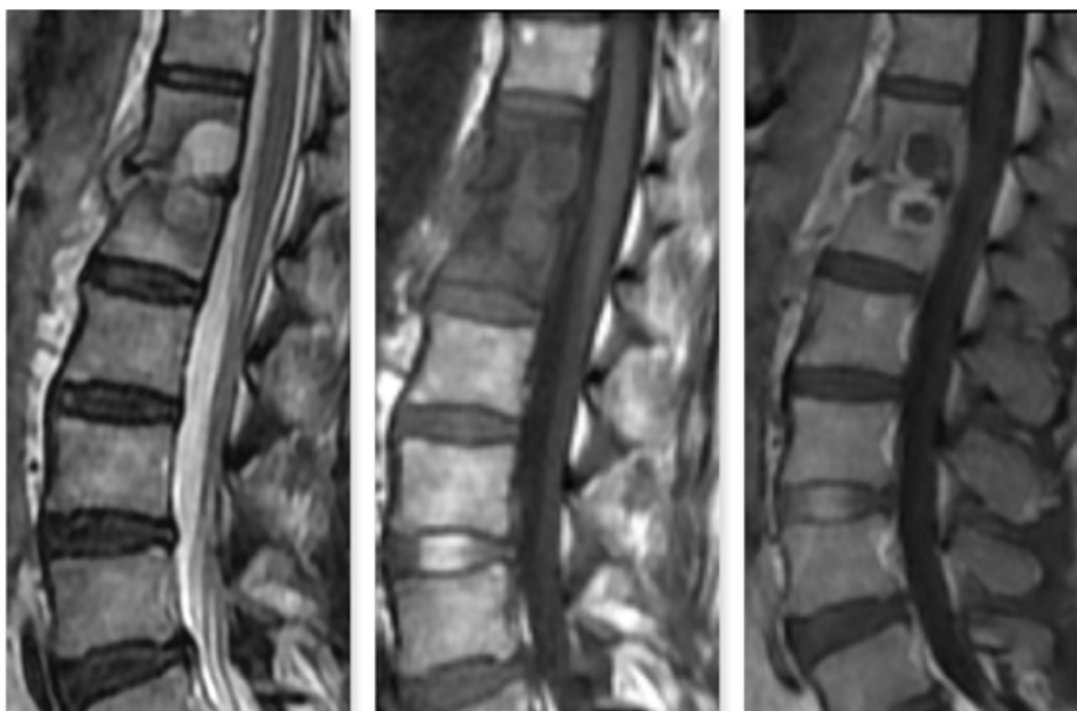


Figure 2. Recurrent vertebral MRI before treatment

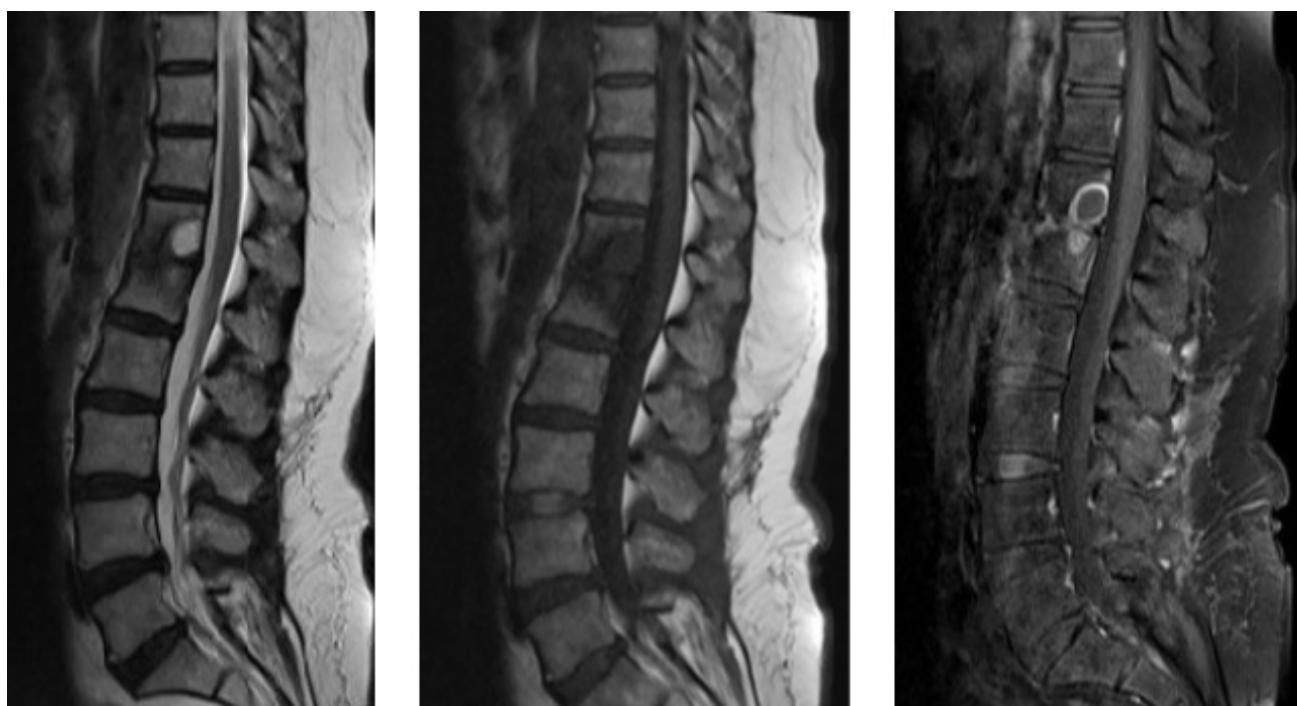

Figure 3. MR scanning at the end of five months

day. In addition, the patient was closely monitored with corset stabilization and mobilization restriction. No progression was detected in the control MRI performed two months later.

A regression was generally observed in radiological findings at control MRI which was screened five months after the antifungal therapy (Figure 3). At the same time, sedimentation (33 mm/h) and CRP (2,9 mg/dl) levels were found to be normal. At the end of five months, complaints and clinical condition and laboratory findings improved. But fluconazole treatment was continued because radiological findings did not regress completely.

Discussion

With the increase in infections caused by *Candida* species in recent years, changes in the variety of species causing these infections have started to be observed. Although *C.albicans* is the most common agent in *Candida* osteomyelitis, cases with *C.parapsilosis* have been reported. In a study by Gamaletsou MN et al., 207 patients with *Candida* osteomyelitis between 1970 and 2011 were examined and non-albicans *Candida* was found as a causative agent in 35% of the cases and *C.parapsilosis* was found in 7% of all cases [3]. Meilleure et al. [4] reported a case of *C.parapsilosis* vertebral osteomyelitis and Cho et al. [5] reported a case of *C.parapsilosis* spondylodiscitis. Although

C.parapsilosis is not the most common cause of vertebral osteomyelitis/spondylodiscitis, it should be kept in mind that it is a causative agent as in the presented case.

Elderly, diabetes, malignancy, immune suppression, malnutrition, intravenous orthopedic operations, trauma are risk factors for vertebral Candida osteomyelitis/spondylodiscitis, but it should be remembered that the disease can be seen without any risk factors [1]. Richaud et al. [2] investigated 28 cases of vertebral Candida osteomyelitis in a retrospective study of the 10-year period. In their study, a Candida infection was detected in 13 of the cases approximately six weeks ago and 26 (93%) of the cases had at least one of the risk factors for invasive fungal infection [2]. Gamaletsou et al. [3] reported that 90% of the patients who were screened for Candida osteomyelitis were not neutropenic.

When searching the literature with “C. parapsilosis” and “spondylodiscitis” keywords in PUBMED only two cases are encountered. Meilleure et al. [4] reported a case of C.parapsilosis lumbar spondylodiscitis, which was detected as an infection of the aortic preterm graft. Cho et al. [5] reported a case of C.parapsilosis spondylodiscitis after lumbar discectomy. In the presented case, no risk factors for the occurrence of Candida spondylodiscitis were found. This is the first case of C. parapsilosis spondylodiscitis which is not an underlying risk factor in the literature.

Early diagnosis of VCO/Candida spondylodiscitis can be difficult until patient develops low back pain or different degrees of neurological deficit due to the symptoms of cord compression. When an early diagnosis cannot be made and proper treatment is not possible, vertebral destruction, spinal cord injury and nerve compression may occur. Antifungal therapy should be initiated after MRI and percutaneous biopsy when VCO/Candida spondylodiscitis is suspected. This treatment can stop the progression of the disease, but in cases of vertebra collapse, spinal cord compression and injury, antifungal therapy should be added to surgery. In a study by Gamaletsou MN, 44% of patients with osteomyelitis were treated with antifungal therapy, 5% with only surgical treatment and 48% with surgery and antifungal therapy [3]. Complete and partial response was obtained in 97% of patients treated with antifungal therapy only [3]. In patients who underwent surgery and antifungal combined therapy 90% success rate was achieved [3]. In another study, 15 of 28 patients with Candida osteomyelitis were given only antifungal therapy and long-term antifungal therapy has been shown to improve survival [2]. In the presented case, success was achieved with five-month of antifungal therapy.

Although the most common causes of spondylodiscitis are Staphylococcus aureus, Pseudomonas aeruginosa and Mycobacterium tuberculosis, it should be noted that Candida may also be the cause. Candida spondylodiscitis is an infection associated with health care like most invasive Candida infections. However, as in this case, it should be kept in mind that Candida spondylodiscitis may develop in immunocompetent patients with no underlying pathology. Suspicion of VCO/Candida spondylodiscitis in patients with long-term low back pain leads to rapid progress in the disease with low treatment success.

Scientific Responsibility Statement

The authors declare that they are responsible for the article's scientific content including study design, data collection, analysis and interpretation, writing, some of the main line, or all of the preparation and scientific review of the contents and approval of the final version of the article.

Animal and human rights statement

All procedures performed in this study were in accordance with the ethical standards of the institutional and/or national research committee and with the 1964 Helsinki declaration and its later amendments or comparable ethical standards. No animal or human studies were carried out by the authors for this article.

Conflict of interest

None of the authors received any type of financial support that could be considered potential conflict of interest regarding the manuscript or its submission.

References

1. Pappas PG, Lionakis MS, Arendrup MC, Ostrosky-Zeichner L, Kullberg BJ. Invasive candidiasis. *Nat Rev Dis Primers*. 2018;4:18026. DOI:10.1038/nrdp.2018.26.
2. Richaud C, De Lastours V, Panhard X, Petrover D, Bruno F, Lefort A. Candida vertebral osteomyelitis (CVO) 28 cases from a 10-year retrospective study in France. *Medicine*. 2017; 96(31):1-7.
3. Gamaletsou MN, Kontoyiannis DP, Sipsas NV, Moriyama B, Alexander E, Roilides E, et al. Candida osteomyelitis: analysis of 207 pediatric and adult cases (1970-2011). *Clin Infect Dis*. 2012;55(10):1338-51.
4. De La Meilleure GEH, Marchau MMB. Candida parapsilosis vertebral osteomyelitis. *Eur J Neurol*. 1995;2:504-7.
5. Cho K, Lee S, Kim E, Eoh W. Candida parapsilosis spondylodiscitis after lumbar discectomy. *J Korean Neurosurg Soc*. 2010;47:295-7.

How to cite this article:

Halil Er, Nisel Özkalay Yılmaz, Evren Sandal, Mehmet Şenoğlu. A case of candida spondylodiscitis in an immunocompetent patient. *Ann Clin Anal Med* 2020;11(Suppl 1): S85-88