



# Interlaminar Lumbar Epidural Steroid Injections in Degenerative Lumbar Spinal Stenosis Patients

## Dejeneratif Stenozlu Hastalarda İnterlaminer Epidural Steroid Enjeksiyonları

ILESI in DLSS

Serbülent Gökhan Beyaz  
Sakarya University Medical School, Anesthesiology, Sakarya, Turkey

This study was presented in NWAC congress on April 2012

### Özet

**Amaç:** Epidural steroid enjeksiyonları DLSS hastaların tedavi modalitelerinden biridir. Hala özellikle yaşlı hastalarda enjeksiyon tedavilerinin etkinliği henüz tam olarak dokümente edilememiştir. Bu çalışmanın amacı DLSS' li hastalarda floroskopi eşliğinde single-shot interlaminer lomber epidural steroid enjeksiyonların (ILESI) etkisini analiz etmektir. **Gereç ve Yöntem:** 1 Kasım 2009-31 Ekim 2010 tarihleri arasında Ordu Üniversitesi Eğitim ve Araştırma Hastanesi Ağrı Kliniği' nde tedavi edilen 115 hasta retrospektif olarak tarandı. DLSS için floroskopi eşliğinde ILESI uygulanan hastalar 1,3,6,9 ve 12. aylarda düzenli olarak takip edilerek Verbal numeric rating skala (VNRS) ve memnuniyet skorları kaydedildi. **Bulgular:** Bu çalışmaya toplam 72 hasta dahil edildi. 1,3,6,9 ve 12. aylarda takip edilen hasta sayıları sırasıyla 72 (%100), 62 (%85), 57 (%78.1), 46 (%63) ve 30 (%41.1) idi. Enjeksiyon öncesi VNRS skorları ortalama  $7.9 \pm 1.6$  iken enjeksiyon sonrası 1,3,6,9 ve 12. aylardaki VNRS skorlarının azalması istatistiksel olarak anlamlı bulundu ( $p < 0.001$ ). 47 hastanın (65.3%) ILESI uygulamasından memnun olduğu görüldü. **Tartışma:** Floroskopi kullanmadan epidural steroid uygulamalarının olası terapötik etkisini beklenenden daha az gösteren çalışmalara rağmen, bu çalışmada 12 aylık takip süresince santral DLSS' li hastalara floroskopi eşliğinde ILESI uygulandığında ağrı skorlarını önemli bir şekilde azalttığı sonucuna varıldı.

### Anahtar Kelimeler

Floroskopi; Epidural Steroid; Stenoz; İnterlaminer; Bel Ağrısı

### Abstract

**Aim:** Epidural steroid injections are one of the treatment modalities for degenerative lumbar spinal stenosis (DLSS) patients although the efficacy of injection therapies has not yet been made clear. This study aims to analyse the effects of single-shot interlaminar lumbar epidural steroid injections (ILESI) under fluoroscopic guidance in DLSS patients. **Material and Method:** 115 patients who were treated in Pain Clinic of Ordu Training and Research Hospital between November 1, 2009 and October 31, 2010 were retrospectively evaluated. These 115 patients underwent ILESI under the guidance of fluoroscopy for degenerative lumbar spinal stenosis. Afterwards, ILESI, patients were followed up regularly in the 1st, 3rd, 6th, 9th and 12th month. Satisfaction scores were evaluated using the North American Spine Society Scale. **Results:** A total of 72 patients were included in this study. In the 1st, 3rd, 6th, 9th and 12th month, the number of patients who were followed were 72 (100%), 62 (85%), 57 (78.1%), 46 (63%), and 30 (41.1%), respectively. Pre-injection VNRS scores were average  $7.9 \pm 1.6$ . Post-injection, VNRS scores in months 1,3,6,9 and 12, dropped significantly ( $p < 0.001$ ). Forty-seven patients (65.3%) reported their satisfaction with the recovery period. **Discussion:** In spite of the studies which show that the therapeutic effect of epidural steroid applications (without fluoroscopy) is smaller or less than expected, our study concluded that ILESI under fluoroscopy significantly decreased the pain scores of central DLSS patients during a 12-month follow-up period.

### Keywords

Floroscopy; Epidural Steroid; Stenosis; Interlaminar

DOI: 10.4328/JCAM.1340

Received: 15.10.2012 Accepted: 03.11.2012 Printed: 01.05.2014

J Clin Anal Med 2014;5(3): 234-8

Corresponding Author: Serbülent Gökhan Beyaz, Sakarya University Medical School, Korucuk Campus, Anesthesiology Center, Sakarya, Turkey.

T.: +90 2642552106 GSM: +905322879490 F.: +90 2642552105 E-Mail: sgbeyaz@gmail.com

## Introduction

Spinal stenosis is the narrowing of the vertebral canal. This narrowing may lead to compression of spinal nerves and nerve roots especially within the lumbar region [1]. The incidence of degenerative lumbar spinal stenosis (DLSS) rises with increasing age. DLSS may lead to limitation of physical activities, radicular pain, and lumbago [2;3]. Overgrowth of bony tissue inside the spinal canal, thickening of the ligamentum flavum, hypertrophy of facet joint, discal herniations, and spondylolisthesis may lead to symptoms via compression of nerves [4].

Neurogenic claudication occurs due to the narrowing of the central spinal canal. DLSS is a result of vertebral degeneration, and therefore, not only is the central spinal canal affected, but also lateral recesses and intervertebral foramina are narrowed [2;3;5]. Unilateral or bilateral monoradicular or polyradicular symptoms may be seen because different regions may be affected. In addition, numbness or sensorial/motor deficits may also manifest.

Since DLSS pathogenesis is multifactorial, vascular, biochemical or biomechanical issues may also accompany DLSS symptoms, in addition to the mechanical situations, which lead to compression or narrowing [6]. If conservative treatment fails, the "narrowed canal" pathology should be treated surgically. Surgical decompression is known as the natural treatment approach [7]. DLSS is the most frequent diagnosis in elderly patients over 65 years of age who have undergone lumbar spinal surgeries [2;7]. Degeneration may increase with advanced age; both stenosis itself and other pathologies related to stenosis may separately cause pain. Background sources of pain may also contribute to complaints and potentiate pain complaints.

Epidural steroid injections may be applied via caudal, interlaminar and transforaminal routes. Success rates are very inconsistent, varying from 20-100% (average 67%) [2;8]. In general, injections of anti-inflammatory and analgesic drugs developed rapidly during the 1990's, especially after routine use of fluoroscopy. Nevertheless, there is limited information about injection therapies in the elderly population [9].

The aim of this study is to evaluate the efficacy of interlaminar epidural steroid injection (Ilesi) treatment in patients who were diagnosed with degenerative primary lumbar spinal stenosis.

## Material and Method

After approval of the university ethics committee, 115 patients who were treated with epidural steroid injections for DLSS between November 1, 2009 and October 31, 2010 were retrospectively evaluated by independent investigators in Ordu University Training and Research Hospital. All the patients were informed about the epidural steroid injections and written informed consents were obtained.

All patients were diagnosed with lumbar spinal pathologies through clinical examination. Experienced radiologists confirmed pathologies revealing the narrowing of the central vertebral canal through magnetic resonance imaging (MRI) results. Central stenosis was characterized by the entire narrowing of the anteroposterior diameter of the spinal canal secondary to ligamentum flavum hypertrophy, central disc protrusion, zygapophyseal joint hypertrophy and/or degenerative spondylolisthesis.

Patients were included if they had lumbar spinal stenosis-related back and/or leg pain more than 6 months and if they had failed with more conservative treatments, including medical or physical therapies. Exclusion criteria included objection to intervention, pregnancy, any contraindications for interventions, (coagulopathy, sepsis, allergy to drugs or contrast material) and previous history of lumbar spinal interventions in other clinics, or history of previous lumbar surgery, neurological deficits, and cauda equina syndrome.

All patients were examined, and imaging studies were reviewed prior to the injection by the author. All injections were standardized to include routine hemogram, biochemical, and coagulation parameters. All injections were administered by one anesthetist and 6-8 hours of fasting protocol was enforced prior to its administration. On the fluoroscopy table, standard anesthesia monitoring was performed. 0.9% NaCl infusion was started intravenously. The intervention area was cleaned with antiseptic iodine-based solution. 1-2 mg midazolam and 25-50 microgram fentanyl were given for conscious sedation purposes. All injections were administered using C-armed fluoroscopy (Genoray Zen 2060, Korea). The intervention area was anesthetized with 0.5-2 ml of 2% prilocaine injected into the skin and subcutaneous tissue.

For the Ilesi approach, an 18 gauge, 3½-inch or 5-inch tuohy needle was advanced directly perpendicular to the skin in a posterior to anterior direction, with the use of the loss-of-resistance to air technique in order to identify the epidural space. In cases where traditional methods failed to reach epidural space, the parasagittal approach was preferred. After negative aspiration for cerebrospinal fluid and blood, 2 ml of non-ionic contrast material was injected to register appropriate contrast spread into the epidural space. Next, a totally 8 ml as combination of 3 ml of saline, and 80 mg (2 ml) of triamcinolone acetonide, and 3 ml bupivacaine 0.25% was injected in the epidural space.

The patients rested on the intervention table for 5 minutes, were transported to the recovery room where they stayed for 2 hours if no complications developed. The complications which occurred during the procedure were recorded. Patients were then asked to sit, stand and walk before rating their pain using the Verbal Numerical Rating Scale (VNRS, 0-10 scale). All the data obtained from the patients were recorded in the patients' charts. The patients discharged from the hospital were asked to refer immediately to our pain clinic in the event that an unexpected situation occurred. On the control days (1, 3, 6, 9 and 12 months after injection), the patients were asked about probable therapeutic effects, VNRS, and any complications, while the responses obtained were recorded in the patient's charts. In addition, data such as age, gender, and MRI findings were also collected.

The patients' charts were reviewed for one year after the initial procedure to determine. In cases of missing data, patients were telephoned and questioned. Modified North American Spine Society (NASS) Patient satisfaction scores were recorded using the 4-grade scale (Table 1).

## Statistical analysis

All data were analyzed using the statistical package SPSS version 15.0 for Windows. A Student's t-test was used to compare

Table 1. Modified North American Spine Society Patient Satisfactory Score

Score	
Bad	No change of complaints; even worse.
Moderate	Epidural steroid helped me but I won't undergo this procedure again.
Good	Most of the complaints are relieved and I would again undergo this procedure if my complaints reappear.
Perfect	Epidural steroid satisfied me and fulfilled my expectations.

parametric data, including demographic characteristics. The Chi-Square test was used to compare groups with regard to satisfaction scores and complications. The ANOVA parametric test for repeated measurements analysis was used to evaluate the improvements in VNRS scores both before and after the procedure. Independent sample t-test analysis was performed for examining differences in pain reduction between the two groups. Data was given as mean ± SD.

**Results**

A total of 72 patient charts were enrolled in this study (Table 2). The average age was 59.9 ± 12.5 years (range 27-83) and 57 of 72 patients (79.2%) were over 50 years of age (Figure 1). Sixteen of the patients were males and 56 of them were females.

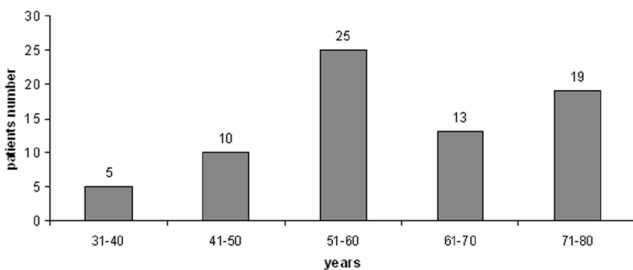


Figure 1. Age Distribution of patients.

When we evaluated MRI results of 72 patients who had complaints pertaining to a narrow central canal, we recorded that 60 patients had diffuse degeneration, 4 patients had spondylolisthesis, 7 patients had facet hypertrophy, and 15 patients had ligamentum flavum hypertrophy together with multiple discal pathologies at various levels (Table 3). The most affected stenotic level was L4-L5.

In the 1st, 3rd, 6th, 9th and 12th month, the number of patients

Table 2. Patient enrollment

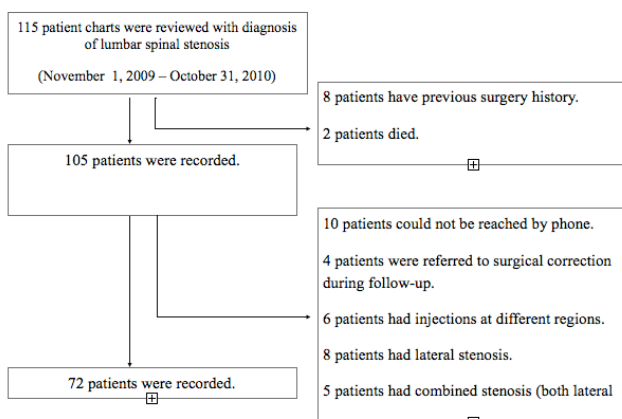


Table 3. Distribution of discal pathologies according to the levels in patients who have lumbar spinal stenosis. Discal pathologies were evaluated by 4 grades; Bulging, protrusion, extrusion and sequestration. No sequestered disc was reported at any level.

	L1-L2 n (%)	L2-L3 n (%)	L3-L4 n (%)	L4-L5 n (%)	L5-S1 n (%)
Bulging	8 (72.7%)	22 (75.9%)	33 (67.3%)	31 (49.2%)	27 (54%)
Protrusion	3 (27.3%)	7 (24.1%)	15 (30.6%)	32 (50.8%)	21 (42%)
Ekstrusion	-	-	1 (2%)	-	2 (4%)
Total	11 (100%)	29 (100%)	49 (100%)	63 (100%)*	50(100%)

Data are given as n (%). \* The most affected stenotic level was L4-L5, p<0.05

who were followed were 72 (100%), 62 (85%), 57 (78.1%), 46 (63%), and 30 (41.1%), respectively. Pre-injection VNRS scores were average 7.9 ± 1.6. Post-injection, VNRS scores in months 1,3,6,9 and 12, dropped significantly (p<0.001, figure 2). There was no significant difference in VNRS scores in the 1st and 3rd months but VNRS scores in the 6th, 9th and 12th month were significantly increased according to the VNRS scores of the 1st month (p<0.05). ILESi was repeated one time for 25 patients and two times for 8 patients.

There were no statistically significant differences between follow-up scores (p>0.05). Satisfaction scores were average 3.2 ± 1.1. Forty-seven patients (65.3%) were classified as perfect or good in terms of satisfaction. (Perfect:34 patients, good: 13 patients, figure 3). Four patients were referred to the neurosurgery department in order to be operated because their pain did not improve during the follow-up period.

No catastrophic complications were encountered. A total of 3 (4.2%) patients had complications (Two patients suffered motor

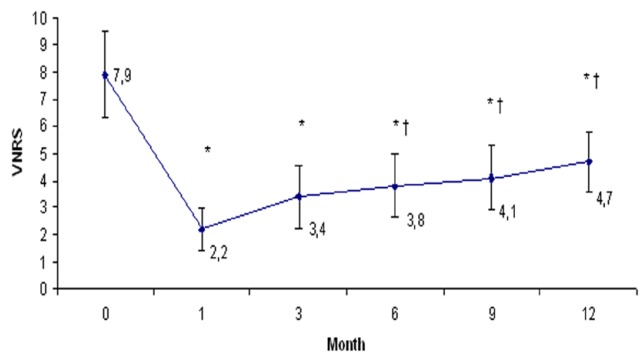


Figure 2. Distribution of VNRS scores versus months.

\*Statistically significant differences between baseline VNRS scores and follow-up scores with ANOVA p<0.001. †Statistical significance of VNRS scores at 6th, 9th and 12th month in relation to the 1st month, p<0.05.

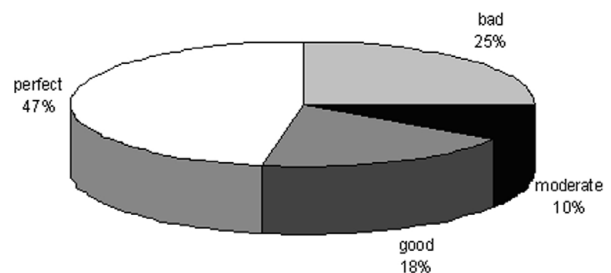


Figure 3. Satisfaction scores of patients. Data is given as a percentage. Perfect-good were sustained as success. \* From patients who were classified as perfect, 12 (35.3%) of them expressed their situation with these words "I feel like I am born again from my mother".

block and one patient had a dural puncture).

## Discussion

This is one of the rare studies that evaluates the results of injection therapies in patients who were specifically diagnosed with degenerative lumbar spinal stenosis. Thus, new information was provided about Ilesi treatment of patients who had pain due to lumbar spinal stenosis. The results of this study were found to be similar to other studies that evaluate epidural steroid treatment under the guidance of fluoroscopy (due to DLSS) [1;2;6;9]. There are two main findings in this study. First, pain relief was provided, especially during the first 3 months after Ilesi in central lumbar spinal stenosis patients. Secondly, high satisfaction scores were obtained after lumbar steroid injections. Campbell et al [10] conducted a study on 84 spinal stenosis patients which investigates the correlation of the spinal canal dimensions and the outcome of epidural steroid injections. They reported that 34 of the patients (40.5%) recovered after Ilesi treatment. However, 50 patients (59.5%), were referred to surgical decompression after 3 attempts of Ilesi once every week. We believe that three different variables with regard to the study methods could have affected the results and therefore clarification is needed. First, all of the injections were administered using the blind technique (without fluoroscopy). Second, three different anesthetists conducted this study and third, the injection level and injectate volume were not standardized. In addition, the reason why epidural steroid injections were applied at one week intervals was not specified. Therefore, the results of this study, rather than clarifying the use of Ilesi for spinal stenosis, only added confusion.

Similarly, another study was conducted on 92 patients with a 16 gauge tuohy needle. The injection was administered at the specific interval near the affected nerve root [11]. When the needle touched lamina, it was pulled back a little and one group of patients received a steroid injectate into muscle tissue whereas the other group received a steroid into the epidural space. They reported that the epidural injection was effective only in the short term (pain relief at 3 months). The conclusion of their study was in accordance with and correlated with many other studies. The common feature of these studies was that all injections were administered without fluoroscopy [12-15]. However, grading of the stenosis was not accomplished in this study. It was not clear on which basis administration of the second epidural injection was decided. There was no explicit information about how pain relief was documented. So, there were many methodological deficits of this study. Therefore, we believe that possible beneficial effects were underestimated (shown less than its actual presence).

Lee et al. [16] conducted a study on 216 spinal stenosis patients who underwent caudal steroid injections under the guidance of fluoroscopy, and they reported that there were no significant differences between short-term or long-term effects. Approximately half of the patients (49.8%) were reported to be satisfied with this procedure. Patients evaluated this short-term effect as "perfect", and the long-term effect as "good". Botwin et al. [17] conducted a prospective study on 34 patients who received caudal steroid injections under the guidance of fluoroscopy. After a follow-up of 6 weeks, 6 months and 12 months,

pain scores decreased more than 50% in terms of pre-injection pain scores. In the 12th month, 52% of the patients reported that they were "somewhat better". In another prospective study, 62 elderly lumbar stenosis patients received lumbar epidural steroid injections [1]. In the 1st and 3rd months, pain scores were reported to be significantly lower than pre-injection pain scores. There was one more small but important detail; when post-injection pain scores were evaluated, it was reported that minor differences might be related to emotional status, socioeconomic level and lifestyle [1;4]. Similarly, our presented study showed 65.3% satisfaction rates after a 12-month-follow-up, together with a significant decrease in pain scores. In the initial months, it was reported that strong efficacy gradually deteriorated during the following months. Barre et al. [2] conducted a retrospective study on 40 patients who underwent caudal epidural steroid injections using fluoroscopy and half of the patients (50%) were successfully treated. They reported a satisfaction rate of 42% in 34 patients. Relatively higher volumes (20-40 ml) of injectates were normally needed for the caudal epidural route. However, this study was conducted with only 8 cc. These large volumes may reach upper lumbar or lower thoracic intervertebral levels [18]. Besides, their age average was  $69 \pm 9.8$  years. Our study revealed higher satisfaction rates which led to less degeneration and complexity. Thus, the appropriate volume of injectate should be administered (via convenient intervertebral level).

Spinal stenosis patients may benefit from epidural steroid applications [19;20] if they had surgical risk or if they were incorporated into a rehabilitation program. If no neurological deterioration is seen, initial conservative therapies may result in surgery delays. However, the postoperative outcome would not change [6;19]. As a result, epidural steroid injections should be presented as an option among non-surgical therapies for spinal stenosis patients.

One limitation of our study was that grading of stenosis was not done. We did not have the MRI films to do this. There were only MRI reports and these reports were reviewed in order to confirm the diagnosis. However, some studies in the literature indicated that grading of stenosis was not important. In another prospective cohort study, there were no significant differences between mild stenosis and severe stenosis patients who received epidural steroids [17]. Campbell et al. [10] reported that success or failure of interlaminar epidural steroid injections was not correlated with spinal canal diameter in lumbar stenosis patients. Another limitation in our study was its retrospective designed nature. Also, a possible limitation of this study is the rule-out prejudice. Ideally, a comparison (control) group is needed in order to determine the efficacy of prospective, randomized injection treatment. Furthermore, we think that the repeated injections (Ilesi was repeated one time for 25 patients and two times for 8 patients) could have influenced the outcome of this study.

In conclusion, early period lumbar epidural steroid applications may improve injection outcomes in patients who do not respond to conservative therapies. Therefore, optimum benefit may be provided via lumbar epidural steroid injections at specific pathology levels under the guidance of fluoroscopy. However, further randomized prospective studies are needed with appropri-

ate methodologies.

### Competing interests

The authors declare that they have no competing interests.

### References

1. Briggs VG, Li W, Kaplan MS, Eskander MS, Franklin PD. Injection treatment and back pain associated with degenerative lumbar spinal stenosis in older adults. *Pain Physician* 2010;13(6):347-55.
2. Barre L, Lutz GE, Southern D, Cooper G. Fluoroscopically guided caudal epidural steroid injections for lumbar spinal stenosis: a retrospective evaluation of long term efficacy. *Pain Physician* 2004;7(2):187-93.
3. Snyder DL, Doggett D, Turkelson C. Treatment of degenerative lumbar spinal stenosis. *Am Fam Physician* 2004;70(3):517-20.
4. Manchikanti L, Pampati V, Fellows B, Rivera JJ, Damron KS, Beyer C, et al. Effectiveness of percutaneous adhesiolysis with hypertonic saline neurolysis in refractory spinal stenosis. *Pain Physician* 2001;4(4):366-73.
5. Kabatas S, Cansever T, Yilmaz C, Kocyigit OI, Coskun E, Demircay E, et al. Transforaminal epidural steroid injection via a preganglionic approach for lumbar spinal stenosis and lumbar discogenic pain with radiculopathy. *Neurol India* 2010;58(2):248-52.
6. Harrast MA. Epidural steroid injections for lumbar spinal stenosis. *Curr Rev Musculoskelet Med* 2008;1(1):32-8.
7. Turner JA, Ersek M, Herron L, Deyo R. Surgery for lumbar spinal stenosis. Attempted meta-analysis of the literature. *Spine (Phila Pa 1976)* 1992;17(1):1-8.
8. Cooper G, Lutz GE, Boachie-Adjei O, Lin J. Effectiveness of transforaminal epidural steroid injections in patients with degenerative lumbar scoliotic stenosis and radiculopathy. *Pain Physician* 2004;7(3):311-7.
9. Botwin KP, Gruber RD, Bouchlas CG, Torres-Ramos FM, Sanelli JT, Freeman ED, et al. Fluoroscopically guided lumbar transformational epidural steroid injections in degenerative lumbar stenosis: an outcome study. *Am J Phys Med Rehabil* 2002;81(12):898-905.
10. Campbell MJ, Carreon LY, Glassman SD, McGinnis MD, Elmlinger BS. Correlation of spinal canal dimensions to efficacy of epidural steroid injection in spinal stenosis. *J Spinal Disord Tech* 2007;20(2):168-71.
11. Wilson-MacDonald J, Burt G, Griffin D, Glynn C. Epidural steroid injection for nerve root compression. A randomised, controlled trial. *J Bone Joint Surg Br* 2005;87(3):352-5.
12. Fukusaki M, Kobayashi I, Hara T, Sumikawa K. Symptoms of spinal stenosis do not improve after epidural steroid injection. *Clin J Pain* 1998;14(2):148-51.
13. Rosen CD, Kahanovitz N, Bernstein R, Viola K. A retrospective analysis of the efficacy of epidural steroid injections. *Clin Orthop Relat Res* 1988;(228):270-2.
14. Ridley MG, Kingsley GH, Gibson T, Grahame R. Outpatient lumbar epidural corticosteroid injection in the management of sciatica. *Br J Rheumatol* 1988;27(4):295-9.
15. Dilke TF, Burry HC, Grahame R. Extradural corticosteroid injection in management of lumbar nerve root compression. *Br Med J* 1973;2(5867):635-7.
16. Lee JW, Myung JS, Park KW, Yeom JS, Kim KJ, Kim HJ, et al. Fluoroscopically guided caudal epidural steroid injection for management of degenerative lumbar spinal stenosis: short-term and long-term results. *Skeletal Radiol* 2010;39(7):691-9.
17. Botwin K, Brown LA, Fishman M, Rao S. Fluoroscopically guided caudal epidural steroid injections in degenerative lumbar spine stenosis. *Pain Physician* 2007;10(4):547-58.
18. Burn JM, Guyer PB, Langdon L. The spread of solutions injected into the epidural space. A study using epidurograms in patients with the lumbosciatic syndrome. *Br J Anaesth* 1973;45(4):338-45.
19. Botwin KP, Gruber RD. Lumbar epidural steroid injections in the patient with lumbar spinal stenosis. *Phys Med Rehabil Clin N Am* 2003;14(1):121-41.
20. Rydevik BL, Cohen DB, Kostuik JP. Spine epidural steroids for patients with lumbar spinal stenosis. *Spine (Phila Pa 1976)* 1997;22(19):2313-7.